

PATIENT PRESENTING CLINICAL SIGNS

Cher C2712 Animals
In Distress has somewhat puffy quality to respirations, rate wnl

RADIOGRAPHIC STUDY OF THE THORAX

SPECIES Right/ left lateral and ventrodorsal views, 3 images in total of the thorax.

Feline **RADIOGRAPHIC FINDINGS**

BREED The lungs are moderately inflated. A moderate generalized bronchial lung pattern is seen throughout the right and left lung. The pulmonary vessels appear normal. No focal consolidations or masses are seen.

DSh The mediastinum is of normal width with no evidence of masses or lymphadenopathy.

SEX Mild age-related redundancy of the aortic arch and cranioventral rotation of the cardiac silhouette is seen. The vertebral heart score is 8 which is within normal limits.

FS The trachea is normal in diameter and course.

AGE Mild esophageal aerophagia is noted.

17yr The pleural space appears normal.

INTERPRETED BY RADIOGRAPHIC DIAGNOSIS

Nele Eley (Ondreka),
DVM Dr. med. vet.,
DipECVDI

- Moderate diffuse bronchial lung pattern consistent with age-related changes or chronic bronchial disease
- Age-related normal presentation of the cardiac silhouette

INTERPRETATION OF FINDINGS & FURTHER RECOMMENDATIONS

HOSPITAL NAME The bronchial pattern may reflect chronic bronchitis, allergic lower airway disease or age-related bronchial thickening. Mild aortic arch rotation is an incidental age-related finding in cats and is per se not of hemodynamic significance. Upper airway disease cannot be excluded based on the radiographs. Correlation with clinical signs is recommended. Endoscopy with bronchoalveolar lavage could be considered for further definition depending on clinical correlation.

REFERRING VET

Renee Ziegler-Post

INVOICE

24371

DATE

04/01/2026



PATIENT

Cher C2712 Animals
In Distress

SPECIES

Feline

BREED

DSh

SEX

FS

AGE

17yr

INTERPRETED BY

Nele Eley (Ondreka),
DVM Dr. med. vet.,
DipECVDI

HOSPITAL NAME

For Cats Only
Veterinary Clinic

REFERRING VET

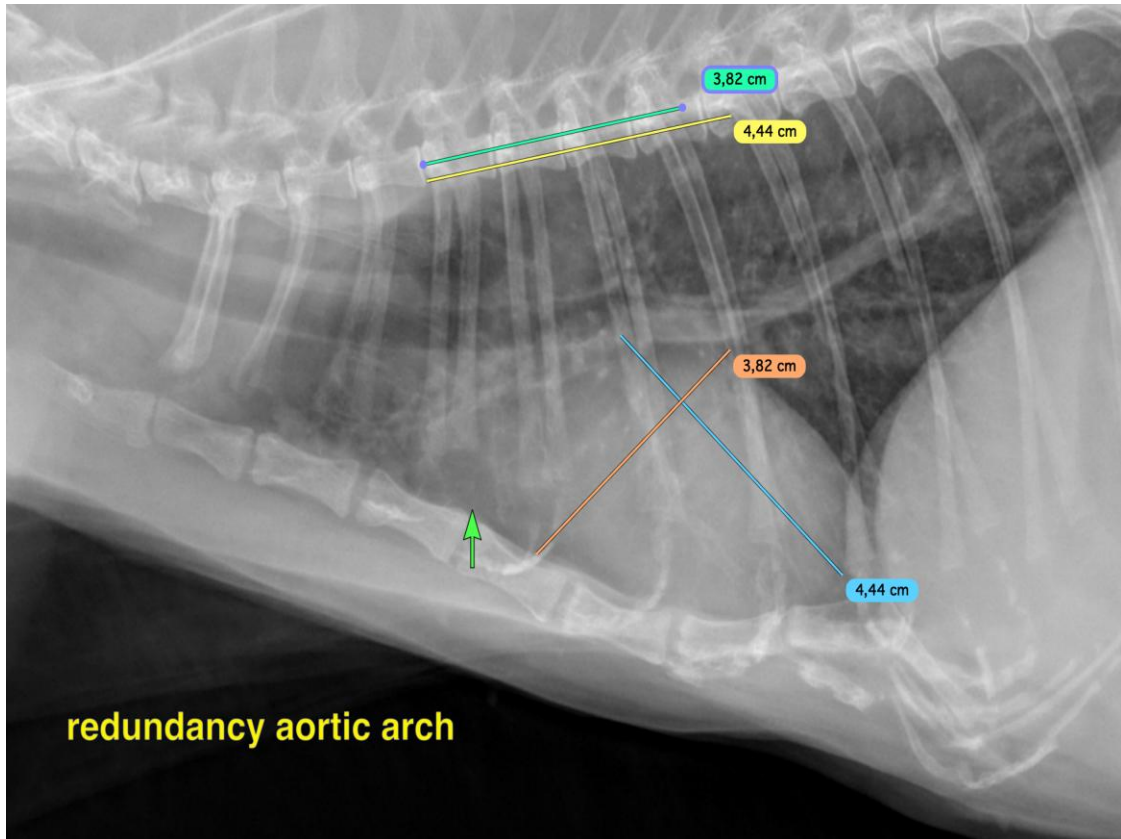
Renee Ziegler-Post

INVOICE

24371

DATE

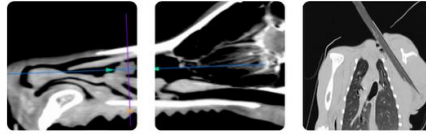
04/01/2026



The information and recommendations provided are based on the images presented by the referring veterinarian. No evaluation can be communicated regarding pathology that was not visible in the image/video clips provided.

Thank you for this referral. If the clinical or image interpretation does not parallel your findings or if I can be of any further assistance please contact me.

Nele Eley (Ondreka), DVM, Dr. med. vet., DipECVDI
European Specialist in Veterinary Diagnostic Imaging, Cert. Radiology,
Senior lecturer University of Giessen/Germany, Veterinary Faculty, Department of Radiology.
info@sonopath.com



Teleradiology

Educational Teleconsultation Services™

PATIENT

Cher C2712 Animals
In Distress

SPECIES

Feline

BREED

DSh

SEX

FS

AGE

17yr

INTERPRETED BY

Nele Eley (Ondreka),
DVM Dr. med. vet.,
DipECVDI

HOSPITAL NAME

For Cats Only
Veterinary Clinic

REFERRING VET

Renee Ziegler-Post

INVOICE

24371

DATE

04/01/2026